

*ABC of clinical electrocardiography***Introduction. I—Leads, rate, rhythm, and cardiac axis**

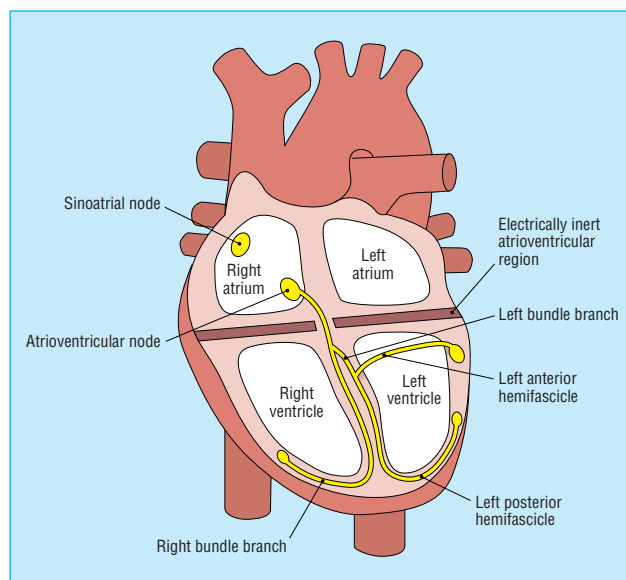
Steve Meek, Francis Morris

Electrocardiography is a fundamental part of cardiovascular assessment. It is an essential tool for investigating cardiac arrhythmias and is also useful in diagnosing cardiac disorders such as myocardial infarction. Familiarity with the wide range of patterns seen in the electrocardiograms of normal subjects and an understanding of the effects of non-cardiac disorders on the trace are prerequisites to accurate interpretation.

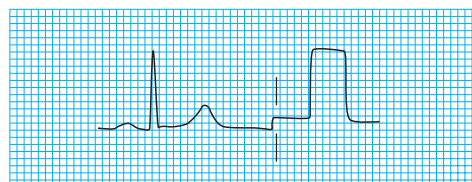
The contraction and relaxation of cardiac muscle results from the depolarisation and repolarisation of myocardial cells. These electrical changes are recorded via electrodes placed on the limbs and chest wall and are transcribed on to graph paper to produce an electrocardiogram (commonly known as an ECG).

The sinoatrial node acts as a natural pacemaker and initiates atrial depolarisation. The impulse is propagated to the ventricles by the atrioventricular node and spreads in a coordinated fashion throughout the ventricles via the specialised conducting tissue of the His-Purkinje system. Thus, after delay in the atrioventricular node, atrial contraction is followed by rapid and coordinated contraction of the ventricles.

The electrocardiogram is recorded on to standard paper travelling at a rate of 25 mm/s. The paper is divided into large squares, each measuring 5 mm wide and equivalent to 0.2 s. Each large square is five small squares in width, and each small square is 1 mm wide and equivalent to 0.04 s.



The His-Purkinje conduction system



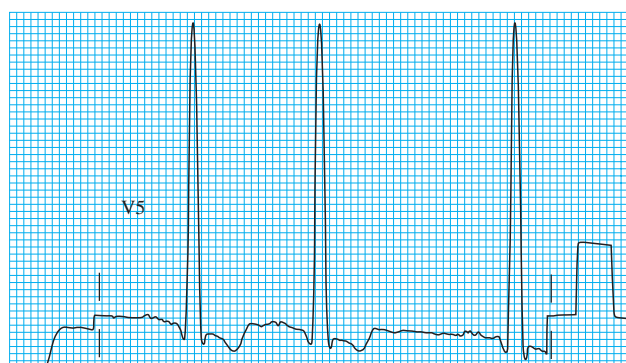
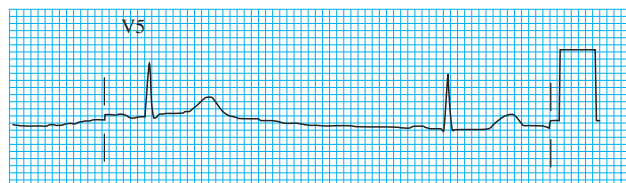
Standard calibration signal

The electrical activity detected by the electrocardiogram machine is measured in millivolts. Machines are calibrated so that a signal with an amplitude of 1 mV moves the recording stylus vertically 1 cm. Throughout this text, the amplitude of waveforms will be expressed as: 0.1 mV = 1 mm = 1 small square.

The amplitude of the waveform recorded in any lead may be influenced by the myocardial mass, the net vector of depolarisation, the thickness and properties of the intervening tissues, and the distance between the electrode and the myocardium. Patients with ventricular hypertrophy have a relatively large myocardial mass and are therefore likely to have high amplitude waveforms. In the presence of pericardial fluid, pulmonary emphysema, or obesity, there is increased resistance to current flow, and thus waveform amplitude is reduced.

The direction of the deflection on the electrocardiogram depends on whether the electrical impulse is travelling towards or away from a detecting electrode. By convention, an electrical impulse travelling directly towards the electrode produces an upright ("positive") deflection relative to the isoelectric baseline,

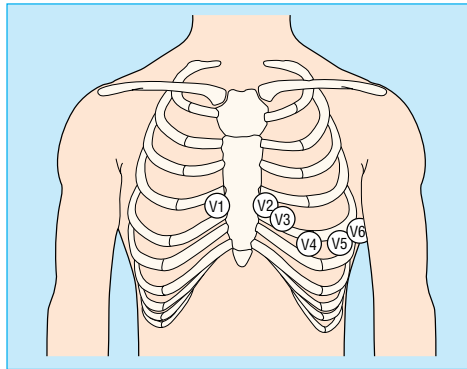
Throughout this article the duration of waveforms will be expressed as 0.04 s = 1 mm = 1 small square



Role of body habitus and disease on the amplitude of the QRS complex. Top: Low amplitude complexes in an obese woman with hypothyroidism. Bottom: High amplitude complexes in a hypertensive man

whereas an impulse moving directly away from an electrode produces a downward (“negative”) deflection relative to the baseline. When the wave of depolarisation is at right angles to the lead, an equiphase deflection is produced.

The six chest leads (V1 to V6) “view” the heart in the horizontal plane. The information from the limb electrodes is combined to produce the six limb leads (I, II, III, aVR, aVL, and aVF), which view the heart in the vertical plane. The information from these 12 leads is combined to form a standard electrocardiogram.



Position of the six chest electrodes for standard 12 lead electrocardiography. V1: right sternal edge, 4th intercostal space; V2: left sternal edge, 4th intercostal space; V3: between V2 and V4; V4: mid-clavicular line, 5th space; V5: anterior axillary line, horizontally in line with V4; V6: mid-axillary line, horizontally in line with V4

The arrangement of the leads produces the following anatomical relationships: leads II, III, and aVF view the inferior surface of the heart; leads V1 to V4 view the anterior surface; leads I, aVL, V5, and V6 view the lateral surface; and leads V1 and aVR look through the right atrium directly into the cavity of the left ventricle.

Rate

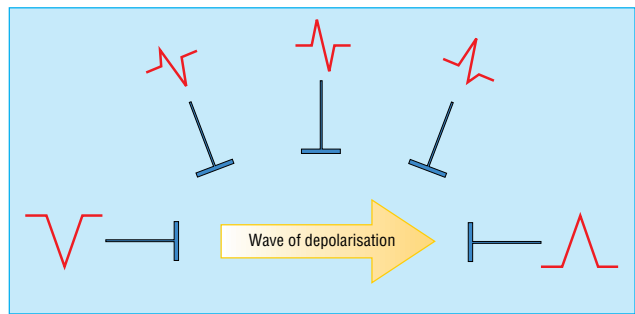
The term tachycardia is used to describe a heart rate greater than 100 beats/min. A bradycardia is defined as a rate less than 60 beats/min (or < 50 beats/min during sleep).

One large square of recording paper is equivalent to 0.2 seconds; there are five large squares per second and 300 per minute. Thus when the rhythm is regular and the paper speed is running at the standard rate of 25 mm/s, the heart rate can be calculated by counting the number of large squares between two consecutive R waves, and dividing this number into 300. Alternatively, the number of small squares between two consecutive R waves may be divided into 1500.

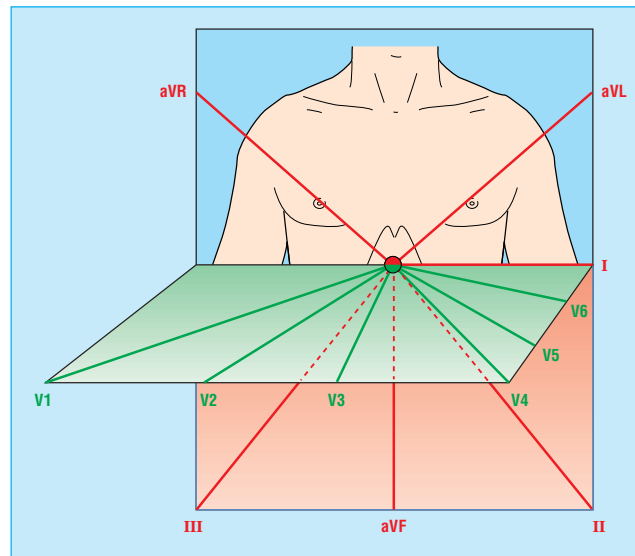
Some countries use a paper speed of 50 mm/s as standard; the heart rate is calculated by dividing the number of large squares between R waves into 600, or the number of small squares into 3000.

“Rate rulers” are sometimes used to calculate heart rate; these are used to measure two or three consecutive R-R intervals, of which the average is expressed as the rate equivalent.

When using a rate ruler, take care to use the correct scale according to paper speed (25 or 50 mm/s); count the correct numbers of beats (for example, two or three); and restrict the technique to regular rhythms.



Wave of depolarisation. Shape of QRS complex in any lead depends on orientation of that lead to vector of depolarisation

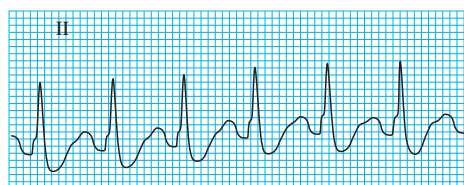


Vertical and horizontal perspective of the leads. The limb leads “view” the heart in the vertical plane and the chest leads in the horizontal plane

Anatomical relations of leads in a standard 12 lead electrocardiogram

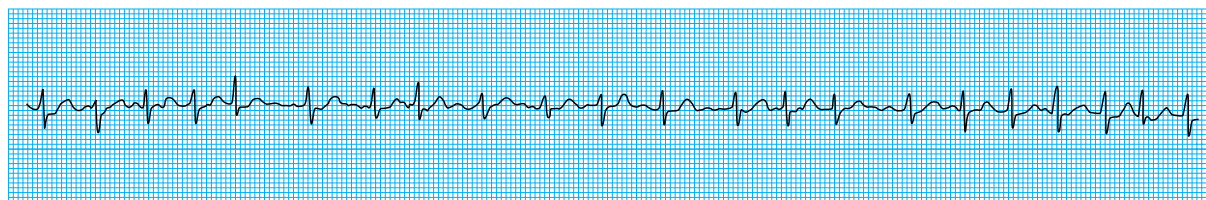
- II, III, and aVF: inferior surface of the heart
- V1 to V4: anterior surface
- I, aVL, V5, and V6: lateral surface
- V1 and aVR: right atrium and cavity of left ventricle

Waveforms mentioned in this article (for example, QRS complex, R wave, P wave) are explained in the next article



Regular rhythm: the R-R interval is two large squares. The rate is 150 beats/min (300/2=150)

When an irregular rhythm is present, the heart rate may be calculated from the rhythm strip (see next section). It takes one second to record 2.5 cm of trace. The heart rate per minute can be calculated by counting the number of intervals between QRS complexes in 10 seconds (namely, 25 cm of recording paper) and multiplying by six.



A standard rhythm strip is 25 cm long (that is, 10 seconds). The rate in this strip (showing an irregular rhythm with 21 intervals) is therefore 126 beats/min (6×21). Scale is slightly reduced here

Rhythm

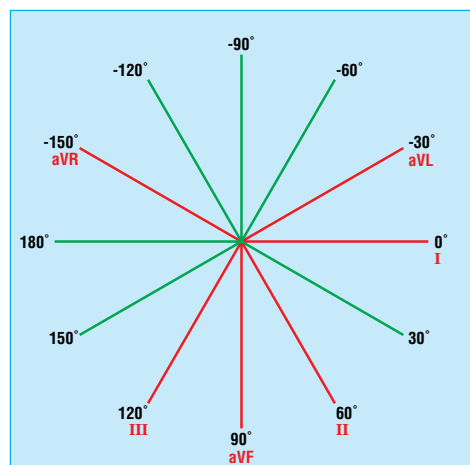
To assess the cardiac rhythm accurately, a prolonged recording from one lead is used to provide a rhythm strip. Lead II, which usually gives a good view of the P wave, is most commonly used to record the rhythm strip.

The term “sinus rhythm” is used when the rhythm originates in the sinus node and conducts to the ventricles.

Young, athletic people may display various other rhythms, particularly during sleep. Sinus arrhythmia is the variation in the heart rate that occurs during inspiration and expiration. There is “beat to beat” variation in the R-R interval, the rate increasing with inspiration. It is a vagally mediated response to the increased volume of blood returning to the heart during inspiration.

Cardiac axis

The cardiac axis refers to the mean direction of the wave of ventricular depolarisation in the vertical plane, measured from a zero reference point. The zero reference point looks at the heart from the same viewpoint as lead I. An axis lying above this line is given a negative number, and an axis lying below the line is given a positive number. Theoretically, the cardiac axis may lie anywhere between 180° and -180° . The normal range for the cardiac axis is between -30° and 90° . An axis lying beyond -30° is termed left axis deviation, whereas an axis $>90^\circ$ is termed right axis deviation.



Hexaxial diagram (projection of six leads in vertical plane) showing each lead's view of the heart

Cardinal features of sinus rhythm

- The P wave is upright in leads I and II
- Each P wave is usually followed by a QRS complex
- The heart rate is 60-99 beats/min

Normal findings in healthy individuals

- Tall R waves
- Prominent U waves
- ST segment elevation (high-take off, benign early repolarisation)
- Exaggerated sinus arrhythmia
- Sinus bradycardia
- Wandering atrial pacemaker
- Wenckebach phenomenon
- Junctional rhythm
- 1st degree heart block

Conditions for which determination of the axis is helpful in diagnosis

- Conduction defects—for example, left anterior hemiblock
- Ventricular enlargement—for example, right ventricular hypertrophy
- Broad complex tachycardia—for example, bizarre axis suggestive of ventricular origin
- Congenital heart disease—for example, atrial septal defects
- Pre-excited conduction—for example, Wolff-Parkinson-White syndrome
- Pulmonary embolus

Several methods can be used to calculate the cardiac axis, though occasionally it can prove extremely difficult to determine. The simplest method is by inspection of leads I, II, and III.

Calculating the cardiac axis

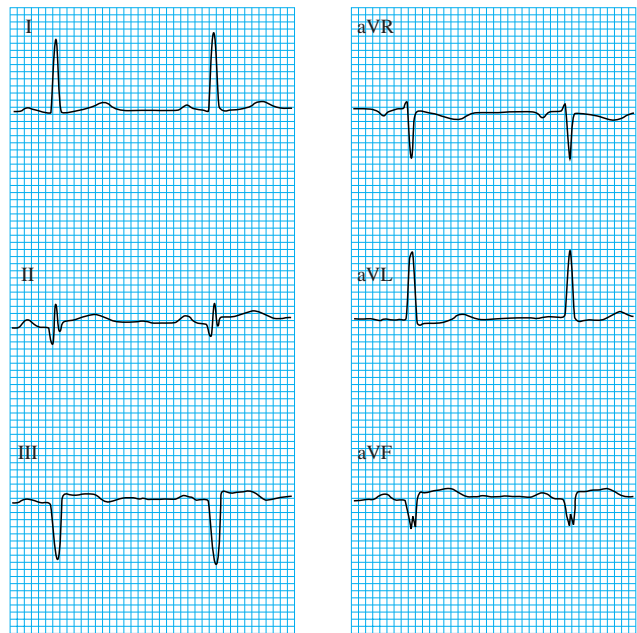
	Normal axis	Right axis deviation	Left axis deviation
Lead I	Positive	Negative	Positive
Lead II	Positive	Positive or negative	Negative
Lead III	Positive or negative	Positive	Negative

A more accurate estimate of the axis can be achieved if all six limb leads are examined. The hexaxial diagram shows each lead's view of the heart in the vertical plane. The direction of current flow is towards leads with a positive deflection, away from leads with a negative deflection, and at 90° to a lead with an equiphasic QRS complex. The axis is determined as follows:

- Choose the limb lead closest to being equiphasic. The axis lies about 90° to the right or left of this lead
- With reference to the hexaxial diagram, inspect the QRS complexes in the leads adjacent to the equiphasic lead. If the lead to the left side is positive, then the axis is 90° to the equiphasic lead towards the left. If the lead to the right side is positive, then the axis is 90° to the equiphasic lead towards the right.

Steve Meek is consultant in emergency medicine at the Royal United Hospitals, Bath.

BMJ 2002;324:415-8



Determination of cardiac axis using the hexaxial diagram (see previous page). Lead II (60°) is almost equiphasic and therefore the axis lies at 90° to this lead (that is 150° to the right or -30° to the left). Examination of the adjacent leads (leads I and III) shows that lead I is positive. The cardiac axis therefore lies at about -30°

The ABC of clinical electrocardiography is edited by Francis Morris, consultant in emergency medicine at the Northern General Hospital, Sheffield; June Edhouse, consultant in emergency medicine, Stepping Hill Hospital, Stockport; William J Brady, associate professor, programme director, and vice chair, department of emergency medicine, University of Virginia, Charlottesville, VA, USA; and John Camm, professor of clinical cardiology, St George's Hospital Medical School, London. The series will be published as a book in the summer.

The emperor's pointer

At first I thought it was just me. I was attending my first scientific meeting, a young doctor eager to acquire new knowledge. It was clear that the first speaker had firmly embraced the concept of the PowerPoint presentation, and he was treating his audience to beautifully coloured slides. Like so many of us, he tended to put just a little too much information on each slide. One of his slides showed a comparison between groups, and we were promised that the third group would differ dramatically from the other two. I saw two lines cross the slide, one close to the other, but no third line. I looked at the key at the bottom of the graph and again saw no more than two groups. I was still waiting for a sudden and victorious appearance of the third group on the graph when the speaker turned to the next slide as if nothing had happened.

At another point, he showed us a pictogram of a human cell that was engaging in complex metabolic activity, with multiple schematics of receptors, proton pumps, and mitochondrial pathways. A small detail of this cell's activity was apparently of great interest to the speaker, for he was enthusiastically aiming his laser pointer at it. I waited for the dot or arrow to appear on the slide, but nothing happened. "Turn it on," I thought, but instead he went on to the next slide, leaving me in the dark about what had been so interesting in that cell. A similar thing occurred a few slides later, but no one in the audience seemed to bother to tell the speaker to turn on his magical pointing device. It had to be me, then. Apparently, his laser pointer was invisible to me, as were some of his wonderfully coloured lines and bars and legends. I couldn't see the emperor's clothes.

And then it dawned on me: I was a man. And what are men, at least some men? Yes, they are colour blind. Presentation after

presentation, I have failed to see the highlights in so many slides. And even this trusted journal joins in the conspiracy. For no particular reason, some issues appear without a date on the cover, such as the first issue in November 2001. Or is it that sometimes, some parts of this journal are invisible to me?

But I can't be alone. Suppose I'm at a large international meeting with an audience of 1500 people, of whom 1000 are male. About 70 of them will be colour blind and therefore not able to see the little red dot or arrow being pointed at that interesting red line. There may be even more, because it seems that a lot of men who once had dreams of becoming a pilot but were turned down because of colour blindness have become doctors.

What can we do about this? Using a big flashing yellow arrow might help; or, as in *Wheel of Fortune*, using a female assistant to point out the area of interest on a slide with a cane (she herself can be guided by the speaker using his pointer); or, perhaps, just putting less data on each slide.

Jurgen A H R Claassen *registrar in geriatric medicine, UMC St Radboud, Nijmegen, Netherlands*

We welcome articles up to 600 words on topics such as *A memorable patient, A paper that changed my practice, My most unfortunate mistake*, or any other piece conveying instruction, pathos, or humour. If possible the article should be supplied on a disk. Permission is needed from the patient or a relative if an identifiable patient is referred to.